

- nized fatal protozoan disease of dogs. *J Am Vet Med Assoc* 192:1269–1285.
8. Dubey JP, Koestner A, Piper RC: 1990, Repeated transplacental transmission of *Neospora caninum* in dogs. *J Am Vet Med Assoc* 197:857–860.
 9. Dubey JP, Lindsay DS: 1989, Transplacental *Neospora caninum* infection in dogs. *Am J Vet Res* 50:1578–1579.
 10. Dubey JP, Lindsay DS: 1990, Neosporosis in dogs. *Vet Parasitol* 36:147–151.
 11. Dubey JP, Lindsay DS: 1993, Neosporosis. *Parasitol Today* 9:452–458.
 12. Dubey JP, Lindsay DS: 1996, A review of *Neospora caninum* and neosporosis. *Vet Parasitol* 67:1–59.
 13. Dubey JP, Metzger FL Jr, Hattel AL, et al.: 1995, Canine cutaneous neosporosis: clinical improvement with clindamycin. *Vet Dermatol* 6:37–43.
 14. Dubey JP, Slife LN, Speer CA, et al.: 1991, Fatal cutaneous and visceral infection in a Rottweiler dog associated with a *Sarcocystis*-like protozoan. *J Vet Diagn Invest* 3:72–75.
 15. Elenkov IJ, Papanicolaou DA, Wilder RL, Chrousos GP: 1996, Modulatory effects of glucocorticoids and catecholamines on human interleukin-12 and interleukin-10 production: clinical implications. *Proc Assoc Am Physicians* 108:374–381.
 16. Eperon S, Brönnimann K, Hemphill A, Gottstein B: 1999, Susceptibility of B-cell deficient C57GL/6 (μ MT) mice to *Neospora caninum* infection. *Parasite Immunol* 21:225–236.
 17. Ferrer L, Rabanal R, Fondevila D, et al.: 1988, Skin lesions in canine leishmaniasis. *J Small Anim Pract* 29:381–388.
 18. Fritz D, George C, Dubey JP: 1997, *Neospora caninum*: associated nodular dermatitis in a middle-aged dog. *Canine Pract* 22:21–24.
 19. Kazmers IS, Daddona PE, Dalke AP, Kelley WN: 1983, Effect of immunosuppressive agents on human T and B lymphoblasts. *Biochem Pharmacol* 32:805–810.
 20. Khan IA, Schwartzman JD, Fonseca S, Kasper LH: 1997, *Neospora caninum*: role for immune cytokines in host immunity. *Exp Parasitol* 85:24–34.
 21. Lundén A, Marks J, Maley SW, Innes EA: 1998, Cellular immune responses in cattle experimentally infected with *Neospora caninum*. *Parasite Immunol* 20:519–526.
 22. McAllister MM, Dubey JP, Lindsay DS, et al.: 1998, Dogs are definitive hosts of *Neospora caninum*. *Int J Parasitol* 28:1473–1478.
 23. Monti DJ: 2000, Hunters hounded as leishmaniasis is diagnosed in Foxhounds. *J Am Vet Med Assoc* 216:1887, 1890.
 24. Ohnuma T, Arkin H, Holland JF: 1980, Differences in chemotherapeutic susceptibility of human T-, B-, and non-T-/non-B-lymphocytes in culture. *Recent Results Cancer Res* 75:61–67.
 25. Perl S, Harrus S, Satuchne (Goldvasser) C, et al.: 1998, Cutaneous neosporosis in a dog in Israel. *Vet Parasitol* 79:257–261.
 26. Poli A, Mancianti F, Carli MA, et al.: 1998, *Neospora caninum* infection in a Bernese Cattle Dog from Italy. *Vet Parasitol* 78:79–85.
 27. Ruehlmann D, Podell M, Oglesbee M, Dubey JP: 1995, Canine neosporosis: a case report and literature review. *J Am Anim Hosp Assoc* 31:174–183.

J Vet Diagn Invest 13:255–258 (2001)

Septicemia associated with *Stenotrophomonas maltophilia* in a West African dwarf crocodile (*Osteolaemus tetraspis* subsp. *tetraspis*)

N. Beth Harris, Douglas G. Rogers

Abstract. A 17-year-old male captive West African dwarf crocodile (*Osteolaemus tetraspis* subsp. *tetraspis*) died 1 month after fighting with a penmate. Abrasions were present on the head and mandible. Necropsy revealed a vegetative valvular lesion of the left atrioventricular valve, miliary foci of necrosis in the endocardium and myocardium, multiple duodenal and rectal ulcers, and serous atrophy of body fat. *Stenotrophomonas maltophilia* was isolated in pure culture from lung, liver, and kidney. Gram-negative bacilli were seen histologically in the valvular lesion and in foci of necrosis in the myocardium, liver, spleen, pancreas, kidney, and intestine. Septic thrombi in multiple tissues, arteritis, and pneumonia were additional histologic lesions. Findings indicated that the crocodile died from acute *S. maltophilia* septicemia, although the primary site of infection was not determined. *Stenotrophomonas maltophilia* is ubiquitous in the environment and is recognized as an important nosocomial pathogen in humans.

Stenotrophomonas maltophilia is a straight or slightly curved nonfermentative gram-negative bacillus that has previously been classified as *Pseudomonas maltophilia* and *Xanthomonas maltophilia*. This bacterium was transferred to the new genus *Stenotrophomonas* because of comparative enzymology data, results of DNA–ribosomal RNA hybridization studies, guanine/cytosine content, and fatty acid composition.¹⁶ Despite earlier reports that *S. maltophilia* had limited pathogenicity,² the bacterium has recently gained im-

portance as a nosocomial pathogen in humans, in which it causes septicemia,^{7,10,11} endocarditis,^{4,12} meningitis,¹³ pneumonia,^{7,10} urocystitis,¹⁷ and wound infection.¹⁸ Human patients considered at risk for *S. maltophilia* infections include the severely debilitated or immunosuppressed, those receiving antimicrobial and/or intravenous therapy, and individuals subjected to invasive surgical procedures.² A protease and elastase elaborated by *S. maltophilia* are believed to be important in the pathogenesis of infection.^{1,15}

Although *S. maltophilia* is now recognized as a significant human pathogen, the role of this bacterium in diseases of animals is less clear. In 1 report, *S. maltophilia* was considered to be the cause of fleece rot in sheep.⁹ *Stenotrophomonas maltophilia* has been isolated from fish,⁶ lizards,

From the Veterinary Diagnostic Center, Department of Veterinary and Biomedical Sciences, University of Nebraska, Lincoln, NE 68583-0907.

Received for publication April 15, 2000.

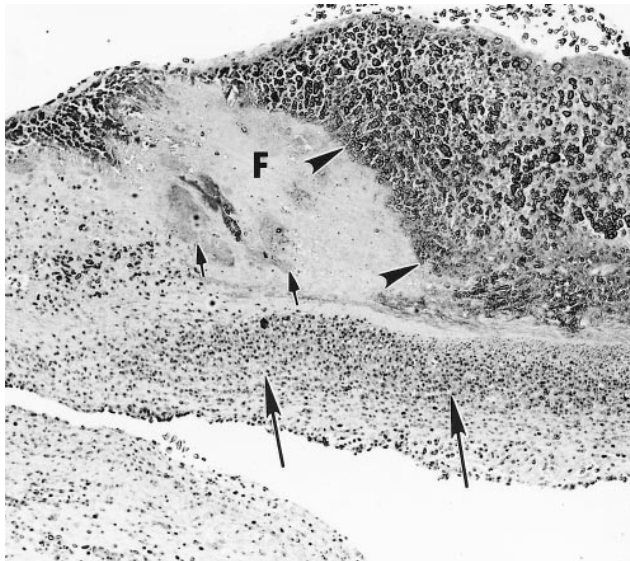


Figure 1. Left atrioventricular valve; crocodile. Vegetative valvular lesion is composed of fibrin (F), erythrocytes, cellular debris (arrowheads), and bacteria (small arrows). Inflammatory cells (heterophils) have infiltrated the valve leaflet (large arrows). HE.

frogs,⁵ and captive snakes,³ but it was never specifically associated with disease in these species. The present report includes laboratory findings indicative of acute septicemia associated with *S. maltophilia* in a crocodile.

A 17-year-old, 13-kg, male West African dwarf crocodile (*Osteolaemus tetraspis* subsp. *tetraspis*) from a local zoo was submitted for laboratory examination 3 hours postmortem. The crocodile had fought with a penmate 1 month earlier, and it had become anorexic and lethargic approximately 1 week prior to death. Three oval abrasions 10–20 × 15–20 cm were present on the dorsum of the head and over the right mandible. Cosmetic necropsy revealed serous atrophy of body fat. In the heart, numerous miliary foci of necrosis

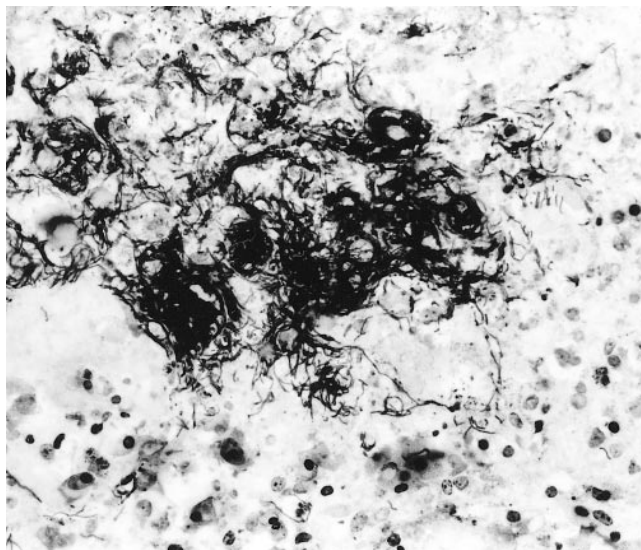


Figure 2. Portion of valvular lesion shown in Fig. 1. Clumps of bacilli are mixed with debris. Warthin-Starry.

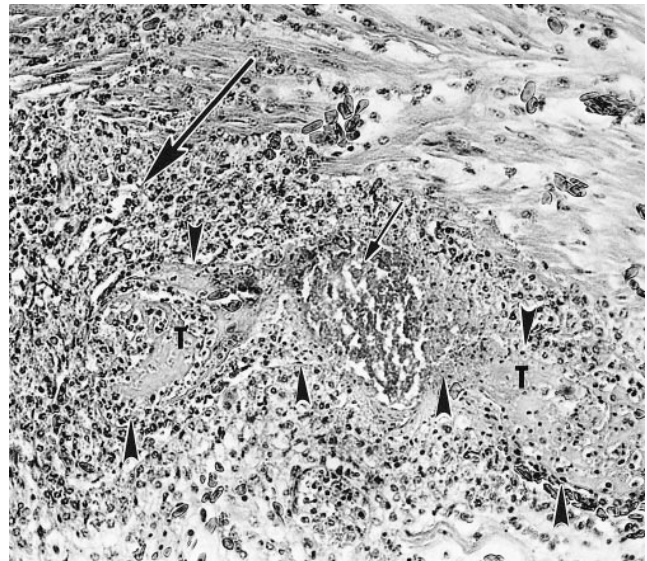


Figure 3. Myocardium; crocodile. A thrombus (T, outlined by arrowheads) with bacteria (small arrow) is adjacent to a focus of necrosis filled with heterophils (large arrow). HE.

were seen in the endocardium and myocardium of the right and left ventricles, and an irregular, raised, yellow-gray vegetative lesion 0.4 × 0.6 cm was present on the atrial aspect of the left atrioventricular (AV) valve. Ecchymotic hemorrhages and 4 ulcers 0.5–1.0 × 0.5–1.0 cm were noted in both the duodenum and rectum.

Specimens of stomach, pancreas, duodenum, jejunum, ileum, rectum, liver, lung, spleen, kidney, and heart including the vegetative valvular lesion were immersed in 10% neutral buffered formalin and routinely processed. Tissue sections were cut at 4 μm and stained with hematoxylin and eosin

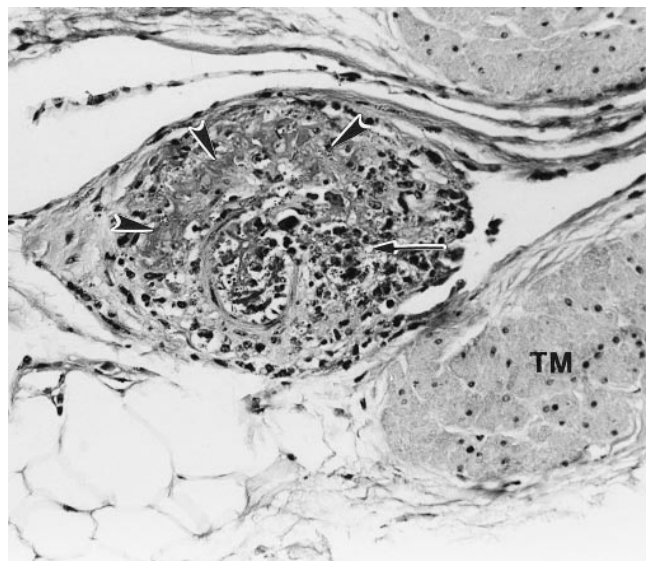


Figure 4. Arteritis in the duodenal serosa of a crocodile. Note the fibrinoid necrosis (arrowheads) and heterophilic debris (arrow) within the arterial tunica media. TM = tunica muscularis. HE.

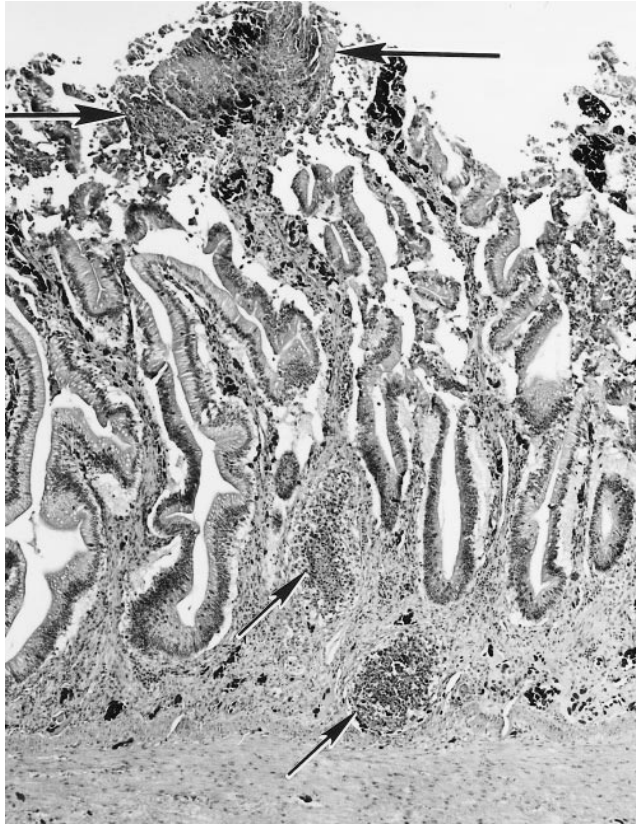


Figure 5. Duodenum; crocodile. Note hemorrhage and necrosis of a villus (large arrows) and aggregates of inflammatory cells (heterophils) within the lamina propria (small arrows). HE.

(HE), Brown and Brenn Gram stain, and Warthin-Starry silver stain for examination by light microscopy.

Specimens of lung, liver, and kidney and multiple specimens of small intestine, including 1 duodenal ulcer, were cultured aerobically at 37 C in 6% CO₂ on tryptic soy agar with 5% sheep blood^a (BA) and on MacConkey agar^a (MAC). Portions of each specimen also were minced and cultured for *Salmonella* in tetrathionate enrichment broth^b at 37 C. This enrichment was followed by overnight culture at 37 C on brilliant green agar^a and on xylose lysine tergitol 4 agar.^b

After 18 hours of incubation, smooth nonpigmented colonies approximately 1 mm in diameter were seen in pure culture on BA and MAC from the lung, liver, and kidney. Smears from individual colonies revealed gram-negative bacilli. The isolate was catalase positive, oxidase negative, and indole negative and was nonfermentative on a triple-sugar-iron slant. Identification of *S. maltophilia* was confirmed using a commercial identification system.^c Mixed bacterial growth was recovered from the specimens of small intestine. *Salmonella* was not isolated from any of the specimens.

In histologic sections of the left AV valve, moderate numbers of heterophils had infiltrated the valve leaflet, fibrin with enmeshed gram-negative bacilli and erythrocytes was adhered to the endocardium (Fig. 1), and there were foci of valvular necrosis of various sizes. Individual bacilli were 0.5–1.0 × 1.0–5.0 μm and were more easily seen in sections stained with Warthin-Starry (Fig. 2).

Gram-negative bacilli associated with histologic lesions of

acute septicemia were seen in all additional specimens collected at necropsy. The myocardium had septic thrombi, foci of necrosis of various sizes infiltrated by heterophils (Fig. 3), and multifocal heterophilic arteritis. Heterophilic arteritis, occasionally with fibrinoid necrosis of the tunica media, was seen in the kidney, stomach, duodenum (Fig. 4), and rectum; hemorrhage, necrosis, heterophilic inflammation (Fig. 5), and septic thrombi accompanied the arterial lesions in these tissues. Colonies of bacilli were in foci of acute necrosis in the spleen, liver, pancreas, duodenum, and rectum. Serofibrinous and heterophilic pneumonia with septic phlebotrombosis was seen in the lung.

The results of histopathologic examination and bacteriologic culture indicated that the crocodile died from acute septicemia associated with *S. maltophilia*. Bacterial thromboembolism secondary to vegetative valvular endocarditis was undoubtedly responsible for the lesions seen in the tissues. Although the vegetative valvular lesion was not cultured bacteriologically and *S. maltophilia* was not isolated from intestinal specimens, gram-negative bacilli were associated histologically with the valvular lesion and necrosis in the duodenum and rectum.

The primary site of *S. maltophilia* infection in this crocodile was not determined. Lung may have been the primary site of infection, because the crocodile had pneumonia. Pulmonary septic phlebotrombosis, as detected histologically, could have resulted from direct extension of the pneumonic process, or it could have developed secondarily from the dissemination of *S. maltophilia* from other site(s). The fact that the crocodile had fought with a penmate prior to death also would lead to speculation that wounds were primary sites of infection. Abrasions were present on the head of the crocodile, but a request for cosmetic necropsy prevented an in-depth examination of these abrasions and a search for other wounds. The environmental source of *S. maltophilia* was not determined, but this bacterium has been isolated from water, sewage, soil, and plants.^{2,6}

The results of this investigation indicate that *S. maltophilia* is a possible pathogen in West African dwarf crocodiles. Whether this bacterium is a primary or an opportunistic pathogen remains to be determined. The crocodile in this report presumably became debilitated and susceptible to *S. maltophilia* infection after fighting with an penmate. Captive crocodilians are highly susceptible to opportunistic gram-negative bacterial infections, especially under stressful conditions.⁸ *Aeromonas*, *Salmonella*, *Arizona*, *Pseudomonas*, and other gram-negative bacteria have been isolated from septicemic crocodilians,^{8,14} and these organisms are often found in the reptilian environment. Changes in diet, overcrowding, fighting, and changes in the environment are believed to be predisposing factors for opportunistic bacterial infections in captive crocodilians.⁸

Sources and manufacturers

- a. Remel, Lenexa, KS.
- b. Difco Laboratories, Detroit, MI.
- c. Crystal Enteric/NonFermenter Identification System, Becton Dickinson, Cockeysville, MD.

Acknowledgements. We thank Mavis Seelmeyer and Drs. E. Denis Erickson and Pushpa Srikumaran for assistance. This report is published as article no. 12966, Agricultural Research

Division, Institute of Agriculture and Natural Resources, University of Nebraska–Lincoln.

References

1. Bottone EJ, Reitano M, Janda JM, et al.: 1986, *Pseudomonas maltophilia* exoenzyme activity as a correlate in pathogenesis of ecthyma gangrenosum. *J Clin Microbiol* 24:995–997.
2. Denton M, Kerr KG: 1998, Microbiological and clinical aspects of infection associated with *Stenotrophomonas maltophilia*. *Clin Microbiol Rev* 11:57–80.
3. Draper CS, Walker RD, Lawler HE: 1981, Patterns of oral bacterial infection in captive snakes. *J Am Vet Med Assoc* 179: 1223–1226.
4. Gutierrez Rodero F, del Mar Masia M, Cortes J, et al.: 1996, Endocarditis caused by *Stenotrophomonas maltophilia*: case report and review. *Clin Infect Dis* 23:1261–1265.
5. Hugh R, Gilardi GL: 1980, *Pseudomonas*. In: *Manual of clinical microbiology*, ed. Lennette EH, Balows A, Hausler WJ, Truant JP, 3rd ed., pp. 288–317. American Society for Microbiology, Washington, DC.
6. Hugh R, Ryschenkow E: 1961, *Pseudomonas maltophilia*, an Alcaligenes-like species. *J Gen Microbiol* 26:123–132.
7. Laing FPY, Ramotar K, Read RR, et al.: 1995, Molecular epidemiology of *Xanthomonas maltophilia* colonization and infection in the hospital environment. *J Clin Microbiol* 33:513–518.
8. Lane TJ: 1996, Crocodilians. In: *Reptile medicine and surgery*, ed. Mader DR, pp. 336–340. WB Saunders, Philadelphia, PA.
9. MacDiarmid JA, Burrell DH: 1986, Characterization of *Pseudomonas maltophilia* isolates from fleece rot. *Appl Environ Microbiol* 51:346–348.
10. Morrison AJ, Hoffman KK, Wenzel RP: 1986, Associated mortality and clinical characteristics of nosocomial *Pseudomonas maltophilia* in a university hospital. *J Clin Microbiol* 24:52–55.
11. Muder RR, Harris AP, Muller S, et al.: 1996, Bacteremia due to *Stenotrophomonas (Xanthomonas) maltophilia*: a prospective multicenter study of 91 episodes. *Clin Infect Dis* 22:508–512.
12. Munter RG, Yinnon AM, Schlesinger, Y, Hershko C: 1998, Infective endocarditis due to *Stenotrophomonas (Xanthomonas) maltophilia*. *Eur J Clin Microbiol Infect Dis* 17:353–356.
13. Nguyen MH, Muder RR: 1994, Meningitis due to *Xanthomonas maltophilia*: case report and review. *Clin Infect Dis* 19:325–326.
14. Novak SS, Siegel RA: 1986, Gram-negative septicemia in American alligators (*Alligator mississippiensis*). *J Wildl Dis* 22: 484–487.
15. O'Brien M, Davis GH: 1982, Enzymatic profile of *Pseudomonas maltophilia*. *J Clin Microbiol* 16:417–421.
16. Palleroni NJ, Bradbury JF: 1993, *Stenotrophomonas*, a new bacterial genus for *Xanthomonas maltophilia* (Hugh 1980) Swings et al. 1983. *Int J Syst Bacteriol* 43:606–609.
17. Vartivarian SE, Papadakis KA, Anaissie EJ: 1996, *Stenotrophomonas (Xanthomonas) maltophilia* urinary tract infection. *Arch Intern Med* 156:433–435.
18. Vartivarian SE, Papadakis KA, Palacios JA, et al.: 1994, Mucocutaneous and soft tissue infections caused by *Xanthomonas maltophilia*: a new spectrum. *Arch Intern Med* 121:969–973.

J Vet Diagn Invest 13:258–260 (2001)

Comparison of GN Hajna and tetrathionate as initial enrichment for salmonellae recovery from swine lymph nodes and cecal contents collected at slaughter

Roger B. Harvey, Robin C. Anderson, Leigh A. Farrington, Robert E. Droleskey, Kenneth J. Genovese, Richard L. Ziprin, David J. Nisbet

Abstract. An epidemiologic survey was conducted to determine the prevalence of salmonellae in swine from 5 farms of an integrated swine operation. The purpose of this study was to evaluate the recovery efficiencies for salmonellae from swine lymph nodes and cecal contents when GN Hajna and tetrathionate were compared as initial enrichments. Salmonellae were isolated from 61% of 645 pigs at slaughter; 324 positive cultures were from lymph nodes, and 224 were from cecal contents. Frequently, pigs had salmonellae isolated from both the lymph nodes and cecal contents. Total isolations, regardless of source, were similar for GN Hajna (247) and tetrathionate (301). There was no difference ($P > 0.05$) in the number of isolations from lymph nodes when GN Hajna enrichment was compared with tetrathionate enrichment (174 vs. 150). However, there was a significant ($P < 0.05$) advantage of utilizing tetrathionate when compared with GN Hajna for isolations from cecal contents (151 vs. 73).

Salmonellosis of swine causes annual economic losses to the swine industry.¹² Because of public health concerns, increased emphasis has been placed on determining the prev-

alence of on-farm salmonellae in swine (Centers for Disease Control and Prevention; Foodnet, 1997 Surveillance Results). Pathogen control systems such as the Hazard Analysis of Critical Control Points program are designed to identify and evaluate the level of pathogen contamination of pigs, carcasses, and pork products. With the emphasis on testing for salmonellae and the time and labor required for traditional culture methods, any improvement in the efficiency of culture techniques would be advantageous. Numerous pre-enrichments, particularly peptone water, have been used for culture of salmonellae.¹ When culturing samples from swine

From the Food and Feed Safety Research Unit, Agricultural Research Service, US Department of Agriculture, 2881 F&B Road, College Station, TX 77845 (Harvey, Anderson, Droleskey, Genovese, Ziprin, Nisbet), and the Department of Epidemiology and Biostatistics, School of Rural Public Health, Texas A&M University Health Science Center, College Station, TX 77843 (Farrington).

Received for publication April 3, 2000.